

## DRUG POINTS

# Tetraparesis associated with colchicine is probably due to inhibition by verapamil of the P-glycoprotein efflux pump in the blood-brain barrier

Uwe Tröger, Hartmut Lins, Jean-M Scherrmann, Claus-Werner Wallesch, Stefanie M Bode-Böger

An 83 year old man had an acute attack of gout. He treated himself with colchicine drops (2 mg in two days) and received diclofenac because of continuous pain. Concurrently he had muscle weakness in his limbs. Four days later he became immobile and was transferred to hospital with flaccid tetraparesis (British Medical Research Council grade II-III). He had no signs of infection, hepatic or renal impairments, or stroke. Laboratory values were normal except a brief increase of creatine kinase to 1288.2 IU/l. Repeated nerve conduction studies did not show any relevant pathology, including normal terminal latencies and F wave latencies. Electromyography subsequently showed signs of lower motor neurone lesion. Muscle biopsy showed one isolated vacuole that could not be related to a colchicine induced myoneuropathy. Analysis of cerebrospinal fluid was unremarkable and indicated only a slight disturbance in the blood-cerebrospinal fluid barrier (protein 548 mg/l). An atypical Guillain-Barré syndrome was clinically diagnosed.

He was also taking 120 mg/day of slow release verapamil continuously for tachyarrhythmia, a sick sinus syndrome of the heart basically controlled by a pace maker, furosemide, acetylsalicylic acid, ambroxol, and theophylline. A tetraparesis due to neuromyopathy induced by colchicines was diagnosed because of concentration-time curves in serum and cerebrospinal fluid.

The diagnosis was revised to neuromyopathy induced by colchicine when excessive colchicine concentrations in serum as well as in cerebrospinal fluid were determined retrospectively using a radioimmunoassay.<sup>1</sup> Although the serum concentration decreased slightly it remained constant in the cerebrospinal fluid in the following days (figure). The calculated half life in serum was increased eightfold compared with a dose and age matched reference population (272 hours *v* 34 hours).<sup>1</sup> The colchicine cerebrospinal fluid to serum ratio of about 50% was much higher than normal (less than 10%). At the follow-up on day 40, he had recovered incompletely but colchicine was not detectable in serum.

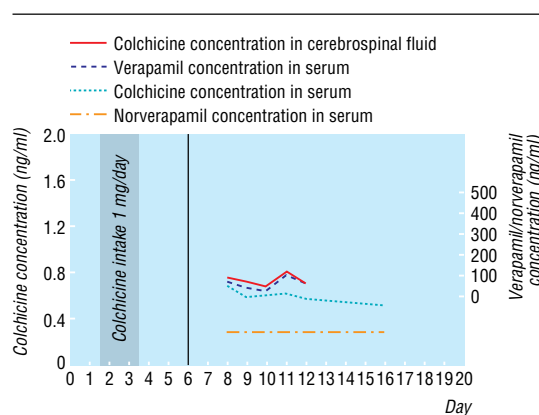
Typical features of colchicine induced myoneuropathy such as high cumulative doses, long term treatment, or renal insufficiency<sup>2</sup> were not found in our case. Verapamil is an inhibitor of CYP3A and a potent inhibitor (with norverapamil threefold stronger) of the P-glycoprotein transporter acting as a blood-brain barrier drug efflux pump.<sup>3</sup> An increase of colchicine uptake was seen in a rat's brain as well as in a rat's plasma by verapamil up to 4.5-fold and 1.65-fold, respectively. These results indicate a dominant responsibility of the P-glycoprotein inhibition for the colchicine accumulation in cerebrospinal fluid.<sup>4</sup> Colchicine is a substrate for CYP3A4 in the liver. Its inhibition might be responsible for increased colchicine serum concentrations.

Colchicine related tetraparesis is most likely due to a pharmacokinetic interaction in the human brain with verapamil and norverapamil. The Drug Commission of the German Medical Profession is not aware of any other cases of this drug interaction.

Funding: None.

Competing interests: None declared.

1 Rochdi M, Sabouraud A, Girre C, Venet R, Scherrmann JM. Pharmacokinetics and absolute bioavailability of colchicine after i.v. and oral adminis-



Colchicine, verapamil, and norverapamil concentrations in serum and cerebrospinal fluid as a function of time

- tration in healthy human volunteers and elderly subjects. *Eur J Clin Pharmacol* 1994;46:351-4.
- Kuncl RW, Duncan G, Watson D, Alderson K, Rogawski MA, Peper M. Colchicine myopathy and neuropathy. *N Engl J Med* 1987;316:1562-8.
  - Pauli-Magnus C, von Richter O, Burk O, Ziegler A, Mettang T, Eichelbaum M, et al. Characterization of the major metabolites of verapamil as substrates and inhibitors of P-glycoprotein. *J Pharmacol Exp Ther* 2000;293:376-82.
  - Drion N, Risede P, Cholet N, Chanez C, Scherrmann JM. Role of P-170 glycoprotein in colchicine brain uptake. *J Neurosci Res* 1997;49:80-8.

doi 10.1136/bmj.38568.639688.F7

This article was posted on [bmj.com](http://www.bmj.com) on 7 September 2005: <http://www.bmj.com/cgi/doi/10.1136/bmj.38568.639688.F7>

## Corrections and clarifications

### Basic transthoracic echocardiography

The authors of this Clinical Review article, Graham S Hillis and Peter Bloomfield, have alerted us to an error in their caption to figure 5 (*BMJ* 2005;330:1432-6, 18 Jun). It should read: "Modified parasternal long axis view showing left atrial myxoma."

### The Law and Ethics of Medical Research: International Bioethics and Human Rights

In this book review by Berna Arda we mistakenly ascribed the wrong sex to the book's author, Aurora Plomer, referring to her as "he" rather than "she" (*BMJ* 2005;331:298, 30 Jul).

### Radiation from CT and perfusion scanning in pregnancy

A mistyped abbreviation led to an error in a unit in this letter by J Valmai Cook and John Kyriou (*BMJ* 2005;331:350, 6 Aug). In the second paragraph, in relation to low dose technetium-99m perfusion lung scans, we should have said 50 megabecquerels (not millibecquerels). Also, we spelt out CTPA as computed tomography for pulmonary angiography, whereas the procedure is more usually referred to as computed tomography pulmonary angiography.

Institute of Clinical Pharmacology, Otto-von-Guericke-University, Leipziger Strasse 44, D-39120 Magdeburg, Germany

Uwe Tröger  
consultant in clinical pharmacology  
Stefanie M Bode-Böger  
professor in clinical pharmacology

Department of Neurology, Otto-von-Guericke-University

Hartmut Lins  
senior registrar in neurology

Claus-Werner Wallesch  
professor in neurology

INSERM U705, CNRS UMR 7157, University Paris 7, University Paris 5, Hôpital F Widal, 200 rue du Faubourg saint-Denis, F-75475 Paris, cedex 10, France

Jean-Michel Scherrmann  
professor in pharmacy

Correspondence to: U Tröger  
[uwe.troeger@medizin.uni-magdeburg.de](mailto:uwe.troeger@medizin.uni-magdeburg.de)

*BMJ* 2005;331:613