

# CME

Follow the link from the online version of this article to obtain certified continuing medical education credits

## Management of traumatic amputations of the upper limb

Thet Su Win,<sup>1</sup> James Henderson<sup>2</sup>

<sup>1</sup>St Andrew's Centre for Burns and Plastic Surgery, Broomfield Hospital, Chelmsford, UK

<sup>2</sup>North Bristol NHS Trust, Frenchay Hospital, Bristol BS16 1LE, UK  
Correspondence to: J Henderson  
jh@jameshenderson.net

Cite this as: *BMJ* 2014;348:g255  
doi: 10.1136/bmj.g255

### bmj.com

Previous articles in this series

- ▶ Managing wheeze in preschool children (*BMJ* 2014;348:g15)
- ▶ Erectile dysfunction (*BMJ* 2014;348:g129)
- ▶ Acute haematogenous osteomyelitis in children (*BMJ* 2014;348:g66)
- ▶ Supporting smoking cessation (*BMJ* 2014;348:f7535)
- ▶ Abortion (*BMJ* 2014;348:f7553)
- ▶ Diagnosis, management, and prevention of rotavirus gastroenteritis in children (*BMJ* 2013;347:f7204)

Traumatic hand or digit amputations can be catastrophic injuries, and often occur in young productive patients.<sup>1-3</sup> Figures from the US national database have shown that amputation injuries represent 1% of all trauma attendances. Finger and thumb amputations were most common (69%), and more proximal amputations of the upper limb contributed a further 9%.<sup>3</sup>

Most patients with amputations are initially managed by non-specialists, before referral to microsurgical units. Good initial management is a key determinant of outcome, and expertise in the management of amputation is only available in specialist centres in most countries.<sup>4</sup> We provide a summary of the initial management of amputation, with emphasis on amputate preservation, indications for replantation (reattachment surgery), and potential outcomes, to help non-specialists manage these emergencies and refer them appropriately.

### What is the assessment and management of traumatic amputation injuries in the emergency department?

#### Assessment of patient

Patients are assessed according to the Advanced Trauma Life Support (ATLS) protocol, and resuscitated as necessary.<sup>4-6</sup> Multiple amputation is an independent risk factor for death.<sup>3</sup> If bleeding vessels are clamped in the emergency department, damage to surrounding structures can occur.<sup>7</sup> Haemorrhage is usually controlled with elevation and non-adherent pressure dressings.<sup>5-7</sup> Although tourniquets are life saving in a military setting,<sup>8</sup> they are rarely needed for civilian injuries. Tetanus prophylaxis is given if indicated, and broad spectrum antibiotics should be commenced.<sup>4-6-7</sup> Blood is cross matched according to the estimated loss and haemodynamic status of the patient.<sup>6</sup> Early and effective analgesia is essential for thorough examination of the patient.<sup>6</sup> We advocate the use of local anaesthetic blocks where possible, because they provide lasting analgesia with minimal side effects.

A detailed history should include time of injury to establish ischaemia time, mechanism of injury, coexisting injuries, age, handedness, occupation and hobbies, general medical status (especially in relation to diabetes, vascu-

### SOURCES AND SELECTION CRITERIA

Few large scale, randomised controlled trials have looked at upper extremity amputation. Data mostly come from multiple case series, case reports, or small trials. We have combined our knowledge with that published in articles identified by PubMed searches, using the terms "amputation" and "replantation" and selecting English language articles relevant to upper extremity replantation.

lar diseases, and smoking), and patient's expectations.<sup>4</sup> All these factors are considered when deciding whether replantation is likely to be technically possible, likely to survive, and whether the replant will be of functional use to the patient.

#### Assessment of amputated part

The amputate is laid on a sterile towel and photographed to minimise handling.<sup>4</sup> Any amputated fragments can be used for skin, bone, or nerve grafting.<sup>4</sup> Radiological imaging of the stump and the amputate in two planes is essential before a decision to attempt replantation, because unexpected bony injuries such as segmental defects may preclude replantation.<sup>4-6</sup>

#### Preservation of amputated part

The amputate should be wrapped in sterile saline soaked gauze, placed in a sealed plastic bag, and either refrigerated at 4°C or placed in iced water solution.<sup>5-6</sup> The amputate should not be placed directly on ice because this can cause frostbite.<sup>9</sup> Muscle has the highest metabolic demand of any tissue, and deteriorates most rapidly during ischaemia. At 20-25°C, irreversible muscle damage may occur after 6 h. Replantation is not recommended when warm ischaemia time has exceeded 6-8 h for a proximal amputation (containing more muscle), and 10-12 h for a digit.<sup>10</sup> Preservation of the amputate as described above can extend the acceptable ischaemia time, and successful digital replantation has been reported after a delay of 94 h.<sup>11</sup> Box 1 shows a guideline for initial assessment and management of a traumatic amputation injury.<sup>4-6</sup>

#### When is referral to a specialist microsurgical centre needed?

All amputations where the amputate is available should be urgently referred to a microsurgical centre. Box 2 shows the information needed by a microsurgical unit receiving a referral. To give realistic expectations from the outset, patients must be made aware that not all amputations are replantable, and that other management options are available (for example, terminalisation (shortening) of stumps; toe to finger transfer (transplant) in digit amputation; and pollicisation of the index finger for thumb amputa-

### SUMMARY POINTS

- Life threatening injuries must be excluded and patient resuscitated before transfer to microsurgical units for replantation
- Critical warm ischaemia time for an amputated limb is typically 6 h, but this depends on cooling of the amputate and the level of amputation (that is, whether there is a muscle component)
- Children have excellent neuroregenerative capacity, and attempts should be made to replant any amputated digits or limbs
- Patients can be expected to achieve 50% sensation and 50% motor function of the replanted part

**Box 1 | Consensus guidelines for initial assessment and management of traumatic amputation injuries<sup>4-6</sup>**

1. ATLS assessment of patient and coexisting injuries
2. Control active bleeding with localised direct pressure or pressure dressing
3. Intravenous access and intravenous fluid or blood, depending on haemodynamic status
4. Send off blood samples for haematology, biochemistry, and coagulation studies, and cross match blood depending on haemodynamic status
5. Broad spectrum intravenous antibiotics
6. If haemodynamically stable, examine the amputation stump and amputate
7. Photograph both the stump and amputate
8. Radiography of both the stump and amputate
9. Determine tetanus status
10. Preservation of amputate—place amputate in saline soaked gauze and seal in a plastic bag. Immerse the bag in icy water. Ensure bag is labelled with patient’s information
12. Cover the stump with a moist, non-adherent sterile dressing, covered by a dry dressing
13. Early and effective analgesia
14. Early referral to a specialist microsurgical centre
15. Safe, rapid transfer of patient and amputate, with all relevant documents and imaging

tions, where the index finger is repositioned to replace the thumb). Replantation should never be guaranteed at this stage. The decision to attempt replantation is made by the patient in discussion with an experienced surgeon who can also offer alternative management options.

**Who to replant?**

The absolute contraindications to replantation are any life threatening injury that takes priority, and multiple major comorbidities that prohibit a lengthy operation<sup>6 12</sup> (from 2-6 h in a single digit replant to >24 h in a multiple digit replant). Rehabilitation after replantation is long and difficult. Patients must therefore be well motivated, and any serious psychiatric or physical illness that would limit rehabilitation are contraindications to replantation.<sup>7 13</sup> There is no predetermined age limit for replantation, and the chronological age of the patient is not as important as their general health and comorbidities. Replantation is not contraindicated for patients with diabetes mellitus or obliterative vascular diseases, but has a higher failure rate.<sup>12</sup> Smoking is detrimental

to replantation; a meta-analysis showed that replanted digits of non-smokers survive 11.8 times more frequently than those of smokers.<sup>14</sup> Smoking cessation is therefore advocated for all patients. Any amputation in a child is considered for replantation, because children have good potential for nerve regeneration and sensory self re-education, resulting in better functional recovery than adults.<sup>15</sup>

**What to replant?**

Replantation is contraindicated for severely crushed or mangled parts, inappropriately stored amputates, or those with profuse contamination.<sup>5 10</sup> Survival outcomes for clean “guillotine” amputations are better than those for crush or avulsion amputations.<sup>16</sup>

Any amputation distal to the elbow is considered for reclamation because these replants could have better functional outcomes than those with prostheses.<sup>17</sup> Multiple digit amputations are considered for replantation of all possible digits. If not all digits are salvageable, the best preserved amputates are replanted to the most useful stumps (heterotopic replantation) or in orientations most likely to ensure maximal function.<sup>18</sup>

Every attempt is made to replant thumb amputations because the loss of a thumb results in a 40-50% loss of hand function.<sup>19</sup> Even a stiff but opposable thumb is of value for prehensile function. Replantation of single fingers in adults is controversial. A case series of 59 patients with single finger replants found that replantation distal to the insertion of the flexor digitorum superficialis tendon on the middle phalanx resulted in improved overall hand function, but this was not the case if the replantation was proximal to this tendon.<sup>20</sup> A recent systematic review of 30 papers reporting 2273 distal digital replants found a high success rate and good functional outcomes.<sup>21</sup> Distal amputation of a single digit is, therefore, a relative indication for replantation. Box 3 summarises the indications for replantation.<sup>5 13</sup>

**What does replantation surgery entail?**

The amputate and stump are debrided in the operating theatre. Nerves, vessels, and tendons are identified and tagged.<sup>5 6 13</sup> Replantation generally begins with bone

**Box 2 | Essential information to include when making a referral for amputation injuries to a specialist centre**

**Injury related information**

- Time of injury to establish ischaemic time
- Mechanism and level of injury
- Radiographical findings for the stump and amputate
- Coexisting injuries
- Haemodynamic status and response to initial management

**Patient related information**

- Age
- Handedness
- Occupation and hobbies
- Medical history (including diabetes and vascular diseases)
- Current treatments and allergies
- Tetanus status
- Smoking history
- From what time is the patient fasted for surgery

**Box 3 | Indications for replantation<sup>5 13</sup>**

**Strong indications**

- Injury factors*
- Thumb amputation
- Multiple digit amputations
- Amputations through the palm, wrist, or forearm
- Patient factors*
- Any amputation in a child

**Relative indications**

- Injury factors*
- Single digit amputation distal to the insertion of flexor digitorum superficialis tendon
- Ring finger avulsion injury
- Patient factors*
- Special needs (for example, professional musician) or patient already has a compromised hand

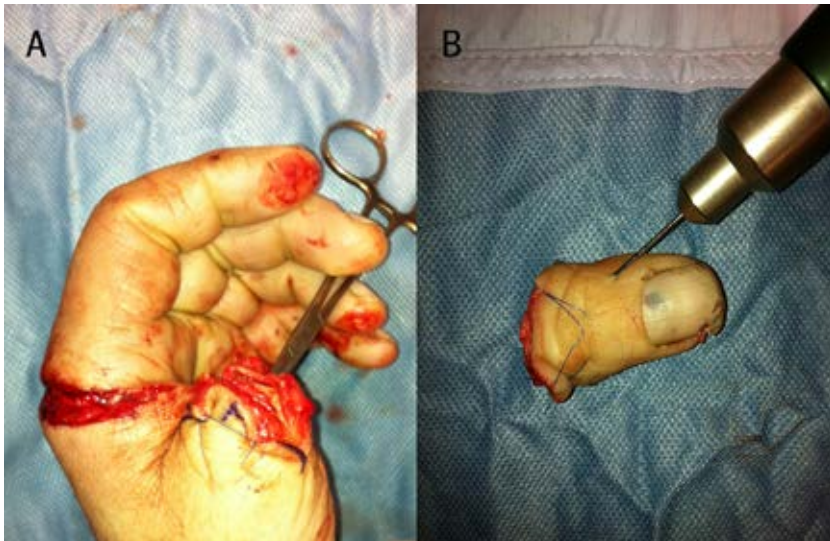

Fig 1 (A) Hand and (B) dominant left thumb of a 54 year old man amputated with a circular saw through the proximal phalanx. A Kirshner wire has been passed anterogradely into the bone of the amputate and will be used to fix the bone

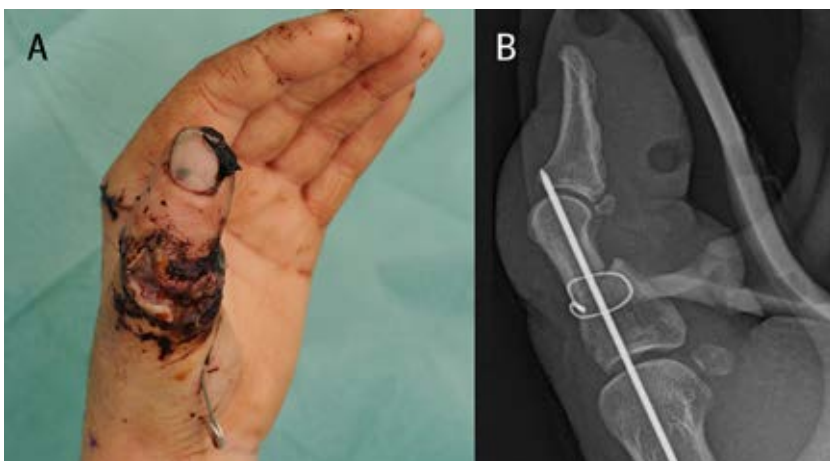


Fig 2 (A) The replanted thumb at one week. There is a small area of split skin graft on the dorsum. The wound just visible on the forearm was for retrieval of the divided flexor pollicis longus tendon, and was also used to harvest vein grafts. (B) Corresponding radiograph showing bone fixation with the Kirshner wire and an interosseous loop of flexible wire. The Kirshner wire is placed obliquely, and does not impinge on either joint

fixation (fig 1)<sup>5 6 13</sup> to provide stability for subsequent repairs. Bone shortening or joint fusion may be required.<sup>6</sup> In a digital replant, our preference is that bone fixation is followed by extensor and flexor tendons repairs, then arteries, nerves, and finally veins. Veins can be elusive in a bloodless finger, and repairing an artery allows perfusion and venous filling. If there is a significant muscle component—such as a forearm amputation—ischæmia time is a concern so blood vessels are repaired early.<sup>5</sup> If the amputate contains muscle, then fasciotomies can prevent compartment syndrome secondary to swelling.<sup>5</sup>

#### What are the potential complications after replantation?

##### Early complications

The most significant early complications are arterial or venous insufficiency, and infection. The focus of post-operative care is to maximise blood flow and decrease

#### Box 4 | The role of the hand therapist

We have a varied role in the postoperative care of a patient after replantation; this involves splintage, mobilisation, support and education, and long term rehabilitation. We usually begin work with the patient 5-7 days after replantation, depending on the level of injury, vascularity of the replant, and if there is any fracture fixation that goes through a joint.

In the early phase after replant, the patient would usually be seen weekly to progress exercises as appropriate. Rehabilitation is arduous and can take many months or even years, and we help make this usually stressful period less so for the patients. One of our important roles is to educate the patient with regards to nerve recovery, tendon and bone healing, the effect of smoking on healing, scar management, and cold intolerance, which helps the patient have an understanding of the injury and a realistic view of recovery. We become well known to our patients, and we are often the first member of the medical team they contact if they have any concerns or questions. It is extremely rewarding to see patients go on to have successful rehabilitation and return to function.

**Carole Watts**, Hand Therapist, St Andrews Centre for Plastic Surgery, Chelmsford

#### TIPS FOR NON-SPECIALISTS

##### Before replantation

Be quick to contact the microsurgical unit once aware of limb amputation

Correct preservation of the amputated part can determine whether replantation is successful

##### Period immediately after replantation

Any suspicion of anastomatic failure or thrombosis mandates urgent exploration in theatre

##### General concerns

Amputation (especially proximal amputation) is often a life changing event, with many patients needing substantial time off work. For some patients, it means the end of employment

Patients may need counselling, psychological support, or medical treatment for depression and help with adjusting to life after amputation

the risk of thrombosis in the anastomosed vessels.<sup>5</sup> The patient is kept warm, well hydrated, and pain-free (pain causes vasoconstriction). Frequent clinical examinations—including skin colour, temperature, turgor, and capillary refill time—are performed, and pulse oximetry can help to monitor limb or digit replants.<sup>22</sup> Arterial thrombosis manifests as a cool, white, pulseless extremity.<sup>5</sup> Any suspicion of anastomatic failure or thrombosis could need urgent surgical exploration.<sup>5 22</sup> A salvage rate of 50% was reported after re-exploration in a series of 42 thumb replants.<sup>23</sup> Venous congestion presents with cyanosis and swelling with a brisk capillary refill.<sup>5</sup> Leeches and anticoagulation may be used to salvage a congested finger,<sup>24</sup> and indeed a series of 19 artery only replants has been performed successfully.<sup>22</sup> In our experience, patients typically stay 6-7 days in hospital before discharge (fig 2).



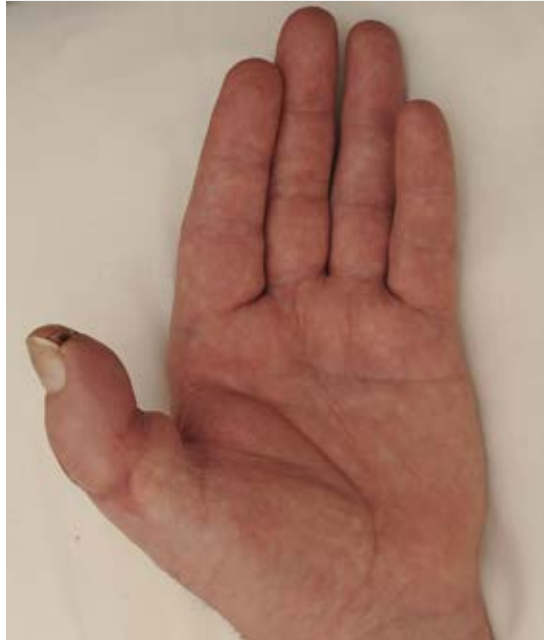

Fig 3 | The hand at eight weeks after replantation. The Kirshner wire was removed after four weeks

#### Late complications

Late complications include cold intolerance,<sup>25</sup> stiffness, tendon adhesions, and bone mal-union or non-union.<sup>13</sup> Cold intolerance usually abates within two years.<sup>26</sup> Tendon adhesions can be divided (tenolysis), but this carries the risk of devascularising a replanted digit; therefore, the procedure is generally reserved for severe cases.<sup>13</sup> Bone growth can still occur after replantation; in a series of 120 children undergoing 162 replants, the overall growth of replanted digits averaged 81% of normal length at maturity.<sup>27</sup>

#### What is the postoperative rehabilitation process?

Rehabilitation is arduous, and generally tailored to the individual patient (box 4). A number of patients require secondary surgery after replantation, including tenolysis, bone grafting for fracture non-union, and tendon or muscle transfers to restore function lost by denervated muscles. These complications could contribute to a substantially longer recovery process.<sup>6</sup> The average return to work time after single digit replantation is reported to be between 2.3 and 3 months<sup>20 28</sup> (fig 3). However, return to work can be longer than one year in patients with arm replants, and many patients fail to return to their previous occupation.<sup>28</sup>

#### What is the long term outlook after upper extremity replantation?

Microsurgical techniques allow many amputated parts to be replanted; however, “success” is harder to measure. Replanted parts may function poorly, being stiff, insensible or painful, potentially leading to a worse outcome than a well functioning stump. It is difficult to make general comments about functional outcomes, because these are very specific to each patient and no two amputations are the same. Recovery is generally assessed using one or more of the following four parameters: ability to work, range of

#### QUESTIONS FOR FUTURE RESEARCH AND ONGOING STUDIES

##### Increasing recovery of sensibility

Investigating the mechanisms of neuronal regeneration<sup>36</sup>

##### Upper limb allotransplantation

Induction of immune tolerance to eliminate the need for long term immunosuppressants<sup>37</sup>

#### ADDITIONAL EDUCATIONAL RESOURCES

##### Resources for healthcare professionals

International registry of hand and composite tissue transplantation ([www.handregistry.com](http://www.handregistry.com))—International network of surgical units where hand and other composite tissue transplantation have been performed, with the aim to register all transplants in order to combine clinical experiences. Free, does not need registration

##### Resources for healthcare professionals and patients

American Society for Surgery of the Hand ([www.assh.org](http://www.assh.org))—US organisation that provides information not only for healthcare professionals, but also for public and patients on hand anatomy, and hand conditions, including replantation. Free, does not need registration

joint motion, muscle power, and recovery of sensibility.<sup>29</sup> Functional outcomes depend on the level of amputation, and in general, the more distal the amputation, the better the functional result of replantation.<sup>30</sup> Several studies have shown that replants achieve a mean of 50% total active motion and 50% grip strength.<sup>31 32</sup> Recovery of sensibility is dependent on the level of injury, need for nerve grafts, and the patient’s age. Children have the greatest neural regenerative capacity,<sup>33</sup> which decreases with age. In adults, the recovery of a measurable two point discrimination (2PD) is rare for a replantation above the elbow, and therefore protective sensation may be all that can be expected.<sup>32</sup> After digit replantation, return of 2PD varies from 50% to more than 90% return of 15 mm or less, as reported in several case series.<sup>25 34</sup> A mean of 7 mm 2PD was found in a systematic review of 2273 distal digital amputations.<sup>21</sup>

#### Future directions

Over the past decade, upper limb replantation has taken a new twist with the advent of hand and digit allotransplantation. Since 1998, when the first successful hand transplant was performed in Lyon, France, a total of 65 hand and upper limb transplants have been performed with encouraging results ([www.handregistry.com](http://www.handregistry.com)).<sup>35</sup> Limb transplantation, however, necessitates the use of long term immunosuppressants, and therefore remains controversial because these are not life saving procedures.

We thank Carole Watts, at Broomfield Hospital, Chelmsford, for hand therapy expertise.

Contributors: JH conceived and designed the review. TSW did the literature review and wrote the original draft, which was revised by JH and approved by TSW, who also double checked the references. JH is the guarantor.

Competing interests: We have read and understood the BMJ Group policy on declaration of interests and declare the following interests: none.

Provenance and peer review: Not commissioned; externally peer reviewed. References are in the version on [bmj.com](http://bmj.com).

Accepted: 6 January 2014